

Intrathyroidal Hyperfunctioning Parathyroid Adenoma : A Case Report

Süleyman Büyükerberber MD¹, Ertuğrul Ertaş MD², Ertan Bülbüloğlu MD², Orhan Şencan MD¹,
Kamran Mahmutyazıcıoğlu MD³, Süleyman Özen MD⁴, N. Engin Aydın MD⁴

As the incidence of thyroid nodules are high in patients with hyperparathyroidism, diagnosis and treatment of intrathyroidal parathyroidal adenomas are difficult. A case of intrathyroidal hyperfunctioning parathyroid adenoma is reported and the diagnosis and treatment of intrathyroidal hyperfunctioning parathyroid adenomas are discussed. [Journal of Turgut Özal Medical Center 1996;3(2):110-112]

Key Words: Intrathyroidal parathyroidal adenoma, primer hyperparathyroidism

Hiperfonksiyon gösteren intratiroidal paratiroid adenomu : olgu sunumu

Hiperparatiroidili hastalarda yüksek sıklıkta tiroid nodülü tespit edilebildiği için hiperfonksiyon gösteren intratiroidal paratiroid adenomlarının tanısı ve tedavisi problemlidir. Bu olgu sunumunda bir vaka nedeniyle intratiroidal yerleşmiş hiperfonksiyon gösteren paratiroid adenomlarının tanı ve tedavisi tartışılmıştır. [Turgut Özal Tıp Merkezi Dergisi 1996;3(2):110-112]

Anahtar Kelimeler: Intratiroidal paratiroid adenomu, primer hiperparatiroidi

Primary hyperparathyroidism occurs in about 1 an every 700 individuals (1). The diagnosis is established by clinical evaluation and persistently elevated serum calcium and parathyroid hormone levels. Parathyroid glands has found completely with in the substance of the thyroid in approximately 2 to 8% of all cases (2,3). Identification of the normal glands is great importance as the search for a specific missing gland (adenoma) can be conducted in a logical sequence based on anatomic and embryologic knowledge of the parathyroids (4). Commonly, no superior parathyroid adenomas were intrathyroidal.

Intrathyroidal parathyroid adenomas were entirely surrounded by thyroid parenchyma in the lower pole (4). Magnetic resonance imaging and ultrasonography detected a high frequency of thyroid nodules in patients with hyperparathyroidism (5). It is difficult, but necessary to evaluate the thyroid nodules in patients with hyperparathyroidism whose abnormal parathyroid tissue cold not be localized.

The methods used for preoperative diagnosis and localization of the hyperfunctioning intrathyroidal parathyroid adenomas, the importance

¹ İnönü University, School of Medicine, Department of Internal Medicine, Malatya

² İnönü University, School of Medicine, Department of General Surgery, Malatya

³ İnönü University, School of Medicine, Department of Radiology, Malatya

⁴ İnönü University, School of Medicine, Department of Pathology, Malatya

of these methods and problems in management of these patients are discussed in this case report.

CASE: A 55 year-old female was admitted to our clinic with complaints of headache and xerostomy and polydipsia for three months.

Physical examination revealed a palpable nodule in right thyroid lobe. The physical examination was normal otherwise.

Serum calcium level was 15.4 mg/dl (normal 9-11), phosphorus level was 1.8 mg/dl (normal 4-6) and parathyroid hormone level was 280 pg/ml (normal 10-65). Thyroid hormone levels was normal. Direct bone X-rays were normal. By neck ultrasonography, a right infero-posteriorly located intrathyroidal mass was detected and felt most likely to represent a thyroid nodule by sonographic criteria. Computerized tomography (CT) of the neck did not give any additional information. The mass was aspirated to rule out other possible parathyroidal adenomas. But no parathyroidal tissue was detected in the aspirate

The patient is thought to have primary hyperparathyroidism due to hyperfunctioning intrathyroidal parathyroid adenoma and surgical neck exploration is performed. The patient was treated by partial thyroid lobectomy of the side of

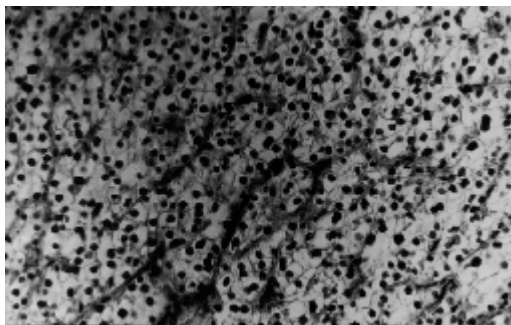
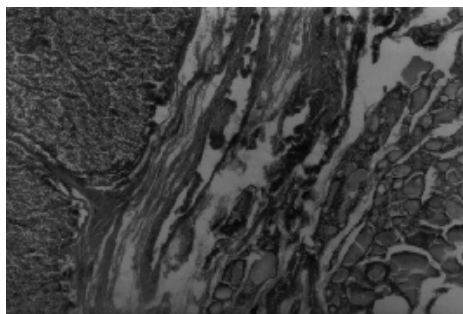


Figure 1a, b. Parathyroid adenoma replacing the infero-posterior of the right thyroid lobe.

the nodule. The parathyroid adenoma was completely replaced the inferior-posterior of right lobe of the thyroid (Figure 1a,b).

After partial thyroidectomy and adenomectomy, a significant decrease in serum concentrations of calcium and parathormone was observed. Serum calcium, phosphorus, thyroid and parathyroid hormone levels were assessed at 3rd and 6th months. Six months after surgery a biochemical and clinical remission of hyperparathyroidism was observed.

DISCUSSION

A more universal benefit is the ability to predict or exclude intrathyroidal and subcapsular parathyroid tumors, thus guiding the decision for thyroid versus thymic exploration in the event of a missing abnormal gland. Magnetic resonance imaging and ultrasonography detect a high frequency of thyroid nodules in patients with hyperparathyroidism (5). Some authors advise sonography as a routine preoperative procedure for primary hyperparathyroidism (6). In addition, if there is previous neck surgery, intrathyroidal parathyroid adenoma can be diagnosed by using parathyroid imaging using a dual tracer (Tl-201 and Tc-99m) and subtraction technique (7). But studies show only limited value for this 99mTc/201Tl subtraction scintigraphy protocol as the initial procedure for localization of intrathyroidal parathyroid tissue prior to surgical exploration (8). The differential diagnosis of intrathyroidal parathyroid adenoma includes thyroid follicular adenoma. In some cases, the possibility of medullary carcinoma of thyroid might also be considered. Immunocytochemical staining for parathormone, thyroglobulin, and calcitonin is valuable in establishing the correct diagnosis (9). The level of parathormon in aspirate can be measured by using an immunoradiometric assay (10). Although absence or low levels of parathormone in the aspirates usually excludes a parathyroid adenoma.

The accuracy of localization studies (ultrasonography, thallous chloride Tl 201-technetium Tc 99m pertechnetate scanning, technetium Tc 99m sestamibi scanning, magnetic resonance imaging, computed tomography, and selective venous catheterization with a parathyroid

hormone assay) decrease morbidity and improve overall results in patients with primary hyperparathyroidism (11).

Management of symptomatic primary hyperparathyroidism is relatively straightforward and the disease can be effectively treated by surgery. Most surgeons agree that patients without previous neck operations do not need to undergo preoperative localization studies. Preoperative localization in patients without prior neck operation is rarely indicated and not proven to be cost-effective (12). In addition, they feel that bilateral neck exploration should be the rule (13). Thyroidectomy can be performed when an abnormal parathyroid gland could not be located in the neck during surgery for hyperparathyroidism.

REFERENCES

1. Levin KE, Clark OH. The reasons for failure in parathyroid operations. *Arch Surg* 1989; 124 (8): 911-4.
2. Davis O, Scanlon EF, Pollak ER, Casey JJ, Victor TA. Bilateral intrathyroidal hyperplastic parathyroid glands. *J Surg Oncol* 1984; 27(4): 271-4.
3. Feliciano DV. Parathyroid pathology in an intrathyroidal position. *Am J Surg* 1992; 164(5): 496-500.
4. Thompson NW, Eckhauser FE, Harness JK. The anatomy of primary hyperparathyroidism. *Surgery* 1982; 92(5):814-21.
5. Funari M, Campos Z, Gooding GA, Higgins CB. MRI and ultrasound detection of asymptomatic thyroid nodules in hyperparathyroidism. *J Comput Assist Tomogr* 1992; 16(4):615-9.
6. Mallette LE, Malini S. The role of parathyroid ultrasonography in the management of primary hyperparathyroidism. *Am J Med Sci* 1989; 298(1): 51-8.
7. Al-Suhaili AR, Lynn J, Lavender JP. Intrathyroidal parathyroid adenoma: preoperative identification and localization by parathyroid imaging. *Clin Nucl Med*. 1988; 13(7):512-4.
8. Sandrock D, Merino MJ, Norton JA, Neumann RD. Parathyroid imaging by Tc/Tl scintigraphy. *Eur J Nucl Med* 1990; 16(8-10): 607-13.
9. Sawady, J, Mendelsohn G, Sirota RL, Taxy JB. The intrathyroidal hyperfunctioning parathyroid gland. *Mod Pathol* 1989; 2(6): 652-7.
10. Sacks BA, Pallotta JA, Cole A, Hurwitz J. Diagnosis of parathyroid adenomas: efficacy of measuring parathormone levels in needle aspirates of servical masses. *Am J Roentgenol* 1994; 163(5):1223-6.
11. Rodriquez JM, Tezelman S, Siperstein AE, Duh QY, Higgins C, Morita E, Dowd C, Clark OH. Localization procedures in patients with persistent or recurrent hyperparathyroidism. *Arch Surg* 1994; 129(8):870-5.
12. National Institutes of Health Consensus Development Conference. Diagnosis and management of asymptomatic primary hyperparathyroidism. *Consens Statement* 1990; 8(7):1-18.
13. Morrow JS, Miller RH. Diagnosis and management of primary hyperparathyroidism. *J La State Med Soc* 1994; 146(3):77-82.

Correspondence address:

Yrd.Doç.Dr. Süleyman BÜYÜKBERBER
İnönü Üniversitesi Tıp Fakültesi
İç Hastalıkları ABD
44100 MALATYA