



# Comparison of the efficacy of epidural blood patch and transnasal sphenopalatine ganglion block in the treatment of postspinal puncture headache

✉ Ebru Canakci<sup>a,\*</sup>, ✉ Ilker Coskun<sup>a</sup>

<sup>a</sup>Ordu University, Faculty of Medicine, Department of Anesthesiology and Reanimation, Ordu, Türkiye

## Abstract

**Aim:** Postspinal puncture headache (PDPH) affects postoperative recovery and patients' quality of life after surgery. PDPH is the most common complication of spinal anesthesia that affects patients' well-being the most. The epidural blood patch (EBP) is the gold standard for interventional treatment of PDPH. Sphenopalatine ganglion block (SPGB), a new noninvasive method for treating PDPH, has come to the forefront. SPGB is non-invasive and very easy to perform compared with EBP. This study aims to compare the efficacy of the two interventional methods in treating PDPH.

**Materials and Methods:** Between January 1, 2018, and February 1, 2023, 30 cases diagnosed with PDPH underwent EBP and 28 SPGB. Case demographics, type of surgery performed, whether complications occurred after the procedure, and the amount of acetaminophen taken within 24 hours were recorded in mg. The VAS scores were recorded 8 times, in the first half hour before and after surgery, and, 1, 2, 4, 6, 12 and 24 hours after the surgery.

**Results:** There was no statistically significant difference between the distributions of sex, type of surgery, and amount of acetaminophen taken after surgery by groups ( $p$  values respectively  $p=0.245$ ,  $p=0.994$ ,  $p=0.131$ ). There was a statistically significant difference between the distributions of 4th-hour values VAS by group ( $p=0.008$ ). There is a statistically significant difference between the groups' distributions of the values of the 6th-hour VAS ( $p=0.016$ ). VAS scores were lower in the epidural blood patch group. There was no difference between the VAS scores in the blood patch and block group in all other measurement periods. Nevertheless, comparing the time variables of the groups, the main effect of time has a statistically significant impact on the VAS ( $p<0.001$ ). There was a significant difference in the sphenopalatine ganglion block and epidural blood patch groups when the pre-surgery VAS value was compared with all post-surgery periods ( $p<0.001$ ,  $p<0.001$ ).

**Conclusion:** The epidural blood patch is the gold standard in treating postspinal headaches. However, it is a difficult procedure to perform since it is an invasive procedure. Sphenopalatine ganglion blockade is a treatment modality with very close efficacy to epidural blood patches in treating postspinal headaches. It can be used as an alternative treatment method in cases that do not accept treatment with the epidural blood patch. As postspinal headache mostly occurs in obstetrics patients, it can be safely used to protect a new-born mother and the baby from the side effects of drugs that pass into the breast milk.

## ARTICLE INFO

### Keywords:

Postspinal puncture headache  
Epidural blood patch  
Sphenopalatine ganglion block

Received: Aug 17, 2023

Accepted: Sep 08, 2023

Available Online: 27.09.2023

DOI:

[10.5455/annalsmedres.2023.08.200](https://doi.org/10.5455/annalsmedres.2023.08.200)



Copyright © 2023 The author(s) - Available online at [www.annalsmedres.org](http://www.annalsmedres.org). This is an Open Access article distributed under the terms of Creative Commons Attribution-NonCommercial-NoDerivatives 4.0 International License.

## Introduction

Postspinal headache is a complication that can occur due to perforation of the dura mater after spinal anesthesia or epidural procedures. Postspinal headache affects patients' postoperative recovery and quality of life after surgery. Postspinal headache is the most common spinal anaesthesia complication affecting patient well-being [1]. It usually

resolves without permanent motor or sensory deficits or sphincter disturbances within a week. Paracetamol and caffeine are recommended for pharmacologic treatment. Postdural puncture headache is defined by the International Headache Society (IHS) as follows: It is a 'bilateral headache' that develops within 7 days after dural puncture and disappears within 14 days, worsens within 15 minutes when standing upright, and regresses within 30 minutes when lying down [2].

\*Corresponding author:

Email address: [canackiebru@gmail.com](mailto:canackiebru@gmail.com) (✉ Ebru Canakci)

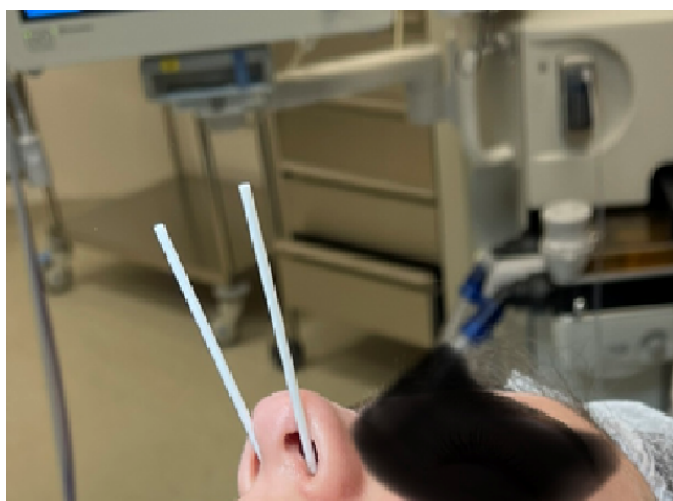
The epidural blood patch (EBP) is the gold standard for interventional treatment of postspinal headaches [3]. Sphenopalatine ganglion block (SPGB), a new noninvasive method for treating postspinal headaches, has come to the fore. After the epidural blood patch is an interventional procedure with infectious complications such as hemorrhage, meningitis, arachnoiditis, and neurologic complications. Sphenopalatine ganglion block is also used to treat migraine and cluster headaches. In recent years, transnasal sphenopalatine ganglion block has also been used to treat postspinal headaches. Sphenopalatine ganglion block is minimally invasive and very easy to perform compared with epidural blood filling [4-6]. This study aims to compare the efficacy of the two interventional methods in treating PDPH.

**Materials and Methods**

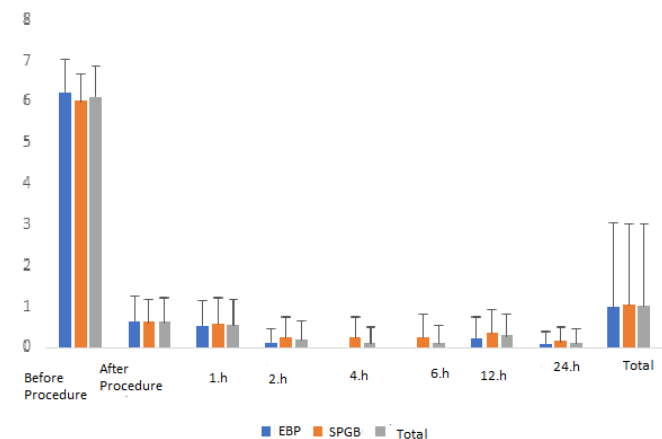
Ethical approval was obtained from the Ordu University Clinical Research ethics committee for our study (Date: 18/03/2021 Decision No: 2021/71). Our study was planned as a prospective, cross-sectional observational clinical study. Between January 1, 2018, and February 1, 2023, 30 cases diagnosed with postspinal headache

underwent epidural blood patch, and 28 cases underwent sphenopalatine ganglion block. The demographic data of the cases, the type of surgery performed, whether or not complications occurred after the procedure, and the amount of acetaminophen taken within 24 hours in mg were recorded. Visual analogue scale (VAS) scores were recorded 8 times, in the first half hour before and after surgery, in the 1st hour, 2nd hour, 4th hour, 6th hour, 12th hour, and 24th hour after surgery. Sphenopalatine ganglion block a case in which we applied block is shown in Figure 1.

An epidural blood patch was first recommended when the patient's VAS score was 6 or higher due to postspinal headache. The epidural blood patch was performed as follows. The patient's consent for the procedure was again obtained, and he was called to the operating room. Two experienced anesthesiologists attended to the patient. The patient was placed in a sitting position and required cleaning and treatment. After covering the procedures, spinal anesthesia was performed on the segment where the needle scar was inserted with an 18-gage Touhy needle (Perifix®, B.Braun, Melsungen, Germany). To collect autologous blood, a tourniquet was placed in the right antebraichial region, and 20 cc of autologous blood was collected from the patient's left brachial vein under absolutely sterile conditions. A syringe filled with 20 cc of autologous blood was given to the other anesthesiologist under sterile conditions. We were instructed to inform when this occurred. The patient was administered 20 cc (minimum 12 cc) of autologous blood. At the end of the procedure, the patient was instructed to lie supine on the neutral plane without moving for at least 45 minutes. Headaches usually disappear within a very short time after the first epidural blood patch. The VAS scores of cases with a VAS score of 6 or more generally resolved to a level of 1-2 points within the first 5-10 minutes. After the epidural blood patch, patients were transferred to the ward. They were hospitalized for at least 24 hours. If they had pain for 24 hours, they were instructed to take 500 mg of acetaminophen orally (Panadol®extra film-coated tablet, GlaxoSmithkline, Şişli, Istanbul, Turkey). The total amount of paracetamol taken by each case was recorded.



**Figure 1.** A case in which SPGB was performed.



**Figure 2.** Mean and standart deviation graph of VAS values.

Sphenopalatine ganglion block was performed in patients diagnosed with postspinal headaches who did not accept epidural blood patch intervention. Consent to the block attempt was obtained from the patient, and he/she was called to the operating room. He/she was placed in the supine position. He/she was instructed to breathe comfortably through both nostrils. It was ensured that there was no obstruction in the nostrils. Two microbiological swab cultures were taken. Two culture swabs were dipped in an ampoule containing 10% lidocaine (%10 Aritmal®, Osel İlaç, Beykoz, Turkey). The culture sticks were kept in the ampoule for at least 10 minutes. It was ensured that the cotton at the end of the culture sticks absorbed the drug well. The culture sticks that had absorbed the 10% lidocaine well were advanced vertically into the posterior pharynx from both nostrils of the patient in the supine position. The culture sticks were left in both nostrils for 10-15 minutes. The culture sticks were then removed. The case was sent to the service after the procedure. Patients

were advised to eat caffeinated food, drink plenty of water, and stay in bed. They were instructed to take 500 mg of acetaminophen orally if they had pain for 24 hours. The total amount of acetaminophen taken by each patient was recorded.

### Statistical analysis

Data were analyzed using IBM SPSS V23. Agreement with normal distribution was assessed using the Shapiro-Wilk test. The chi-square test was used to compare categorical variables by group. The independent two-sample t-test was used to compare normally distributed data by group, and the Mann-Whitney U test was used to compare non-normally distributed data. The generalized linear model's method was used to examine the effects of the main effects of group and time and interaction on the VAS values, and multiple comparisons were performed with the Bonferroni test. Results of analysis Mean  $\pm$  sd for quantitative data. Categorical data as variance and median minimum-maximum) were presented as frequency (percentage). The significance level was taken as  $p < 0.050$ .

### Results

The demographic characteristics of the groups are shown in Table 1.

There was no statistically significant difference between the mean age, weight, height, and body mass index values in the groups ( $p > 0.050$ ).

The comparison of categorical variables by groups is shown in Table 2.

There was no statistically significant difference between the distributions of sex, type of surgery, and amount of acetaminophen taken after surgery by groups ( $p$  values respectively  $p = 0.245$ ,  $p = 0.994$ ,  $p = 0.131$ ).

The comparison of VAS by group and time is shown in Table 3.

The main effect of the group had no statistically significant effect on VAS ( $p = 0.141$ ). The mean of the EBP group was 0.983, and the mean of the SPGB group was 1.054. VAS did not differ between groups. The main effect of time has a statistically significant influence on VAS ( $p < 0.001$ ). In other words, in both groups, the VAS scores measured before the procedure and the VAS scores measured in all time periods after the procedure were found to be statistically significantly lower. The pre-treatment average was 6.121, and the post-treatment average was 0.621. The 1st-hour average is 0.552; the 2nd-hour average is 0.190; the 4th-hour average is 0.121; the 6th-hour average is 0.121; the 12th-hour average is 0.293; and the 24th-hour average is 0.121. VAS Average values differ over time. This difference is since the average before the procedure is higher than the averages of the other times, and the averages before the procedure and due to the high 1st hour are higher than the averages of the 2nd hour, 4th-hour, 6th-hour, 12th hour and 24th hour averages. The interaction between group and time had no statistically significant effect on the VAS ( $p = 0.220$ ).

Descriptive statistics of VAS values by group and time are presented in Table 4.

A comparison of VAS between and within groups is shown in Table 5.

A statistically significant difference was found between the distributions of the values of the 4th-hour VAS between the groups ( $p = 0.008$ ). The median VAS of both groups was 0.000. This difference was due to the rank average. While the median rank of the EBP group was 26.50, the median rank of the SPGB group was 32.71. There was a statistically significant difference between the distributions of the values of the 6th-hour VAS according to the groups ( $p = 0.016$ ). The median VAS of both groups was 0.000. This difference was due to the rank average. While the median rank of the EBP group was 27.00, the median rank of the SPGB group was 32.18. There is no statistically significant difference between the distributions of the VAS at other times by the groups ( $p > 0.050$ ). Nevertheless, comparing the time variables of the groups, the main effect of time has a statistically significant impact on the VAS ( $p < 0.001$ ). There was a significant difference in the sphenopalatine ganglion block and epidural blood patch groups when the pre-procedure VAS value was compared to all post-procedure periods ( $p < 0.001$ ,  $p < 0.001$ ).

There was a statistically significant difference between the medians of the VAS over time in the EBP group ( $p < 0.001$ ). The median for treatment was 6.000, the median for post-treatment was 1.000, and the medians for the other time points were 0. This difference was since the median before surgery was higher than the median for the other time points. In the SPGB group, there was a statistically significant difference between the medians of VAS over time ( $p < 0.001$ ). The median for treatment was 6.000, the median for post-treatment was 1.000, and the medians for the other time points were 0. This difference was due to the higher median before surgery than the median of the other times.

The mean and standard deviation of VAS are shown in Figure 2.

### Discussion

As a result of our study, it was found that the amount of paracetamol consumed within 24 hours was no statistically significant. Although it did not reach the statistical significance level, it was determined that less amount of paracetamol was consumed in the epidural blood patch group ( $p = 0.131$ ). When comparing the VAS in the different measurement periods, it was found that the VAS were lower in the 4th and 6th hour in the group with the epidural blood patch. VAS were lower also in the other measurement periods at the 1st hour, 2nd hour, and 6th hour. Nevertheless, comparing the time variables of the groups, the main effect of time has a statistically significant impact on the VAS ( $p < 0.001$ ). In the sphenopalatine ganglion block group and the epidural blood patch group, there is a significant difference when the pre-procedure VAS value is compared to all post-procedure periods ( $p < 0.001$ ). In both the block and blood patch groups, there is a significant difference between the preprocedural VAS score and the postprocedural VAS score.

The epidural blood patch was superior to the sphenopalatine ganglion block, with no obvious superiority. Conservative treatments with intravenous hydration, caffeine, and

**Table 1.** The demographics of the groups and the total amount of acetaminophen taken in 24 hours.

	EBP		SPGB		Test statistics	p
	Mean±SD	Mean (min-max)	Mean±SD	Mean (min-max)		
Age	38.2 ± 13.3	32.0 (23.0 - 66.0)	38.9 ± 13.4	36.0 (23.0 - 66.0)	t=-0.197	0.845
Weight	73.9 ± 11.0	78.0 (55.0 - 93.0)	73.7 ± 10.5	78.0 (55.0 - 91.0)	t=0.078	0.938
Height	166.3 ± 9.1	166.0 (154.0 - 182.0)	165.8 ± 7.9	166.0 (155.0 - 182.0)	t=0.244	0.808
Body Mass Index	26.6 ± 2.5	27.2 (22.4 - 30.9)	26.7 ± 2.5	27.5 (22.4 - 30.9)	t=-0.148	0.883

t: Two independent samples t-test statistics, U: Mann-Whitney U-test statistics.

**Table 2.** Comparison of categorical variables by groups.

	EBP	SPGB	Total	Test statistics	p
<b>Gender</b>					
Female	22 (73.3%)	24 (85.7%)	46 (79.3%)	$\chi^2=1.353$	0.245
Male	8 (26.7%)	4 (14.3%)	12 (20.7%)		
<b>Type of Operation</b>					
Gynaecological	8 (26.7%)	8 (28.6%)	16 (%27.6)	$\chi^2=0.085$	0.994
Obstetrics	14 (46.7%)	12 (42.9%)	26 (%44.8)		
Orthopedics	5 (16.7%)	5 (17.9%)	10 (%17.2)		
General surgery	3 (10%)	3 (10.7%)	6 (%10.3)		
<b>Post-procedure complication</b>					
None	30 (100%)	28 (100%)	58 (100%)	-	-
<b>The amount of paracetamol consumed after the procedure</b>					
0	26 (89.7%)	19 (67.9%)	45 (78.9%)	$\chi^2=4.073$	0.131
500 mg	2 (6.9%)	6 (21.4%)	8 (14%)		
1000-1500 mg	1 (3.4%)	3 (10.7%)	4 (7%)		

$\chi^2$  : Chi-square test statistic mg: milligram.

**Table 3.** Comparison of VAS by group and time.

	Test statistics*	SD	p
Group	2.165	1	0.141
Time	6578.73	7	<0.001
Group * Time	9.486	7	0.220

\*Wald chi-square test statistics, SD: Degrees of freedom.

**Table 4.** Descriptive statistics of VAS by group and time.

	EBP	SPGB	Total
Before the procedure	6.233 ± 0.817	6.000 ± 0.667	6.121 ± 0.751 <sup>c</sup>
After procedure	0.633 ± 0.615	0.607 ± 0.567	0.621 ± 0.587 <sup>b</sup>
1st-hour	0.533 ± 0.629	0.571 ± 0.634	0.552 ± 0.626 <sup>b</sup>
2nd-hour	0.133 ± 0.346	0.250 ± 0.518	0.190 ± 0.438 <sup>a</sup>
4th-hour	0.000 ± 0.000	0.250 ± 0.518	0.121 ± 0.378 <sup>a</sup>
6th-hour	0.000 ± 0.000	0.250 ± 0.585	0.121 ± 0.422 <sup>a</sup>
12th-hour	0.233 ± 0.504	0.357 ± 0.559	0.293 ± 0.530 <sup>a</sup>
24th-hour	0.100 ± 0.305	0.143 ± 0.356	0.121 ± 0.329 <sup>a</sup>
Total	0.983 ± 2.058	1.054 ± 1.958	1.017 ± 2.009

a-c: There is no difference between times with the same letter.

methylxanthines can treat headaches after a spinal block. However, conservative treatments may take up to 48 hours

to show their effects [7-9]. Considering that postspinal headache is more common after cesarean section, especially in young adult patients, it should be treated quickly. This is because a postpartum woman already has pain in her chest and at the incision site. In addition, terrible headaches increase her suffering. This may even lead to feeding and care problems in newborns. An epidural blood patch is a method that stops the headache immediately, yet it is an invasive method. It has side effects such as difficulties providing sterility conditions, temporary fever, and re-creation of dura defect with 18 Gauge Touhy needle. Moreover, administering 30 ml or more of the patient's blood when performing the epidural blood patch may lead to an important complication such as radiculopathy [8]. When we look at the results of our study, the VAS scores of the cases in the epidural blood patch group regressed after the procedure, 30 minutes (=after the procedure) and quickly in the 1st hour. In the sphenopalatine ganglion block group, the VAS scores of the cases also regressed after 30 minutes and 1 hour.

A literature review shows that SPBG has been used for postoperative pain control in endoscopic sinus surgery [10]. Levin et al. also used it to treat persistent headaches that developed after coronavirus disease [11]. SPGB is on its way to becoming a new modality for treating acute and chronic headaches.



**Table 5.** Comparison of VAS between and within groups.

	EBP		SPGB		Test statistics	p
	Mean±SD	Mean (min-max)	Mean±SD	Mean (min-max)		
Before procedure	6.230 ± 0.817	6.000 (5.000 - 8.000) <sup>a</sup>	6.000 ± 0.667	6.000 (5.000 - 8.000) <sup>a</sup>	U=367	0.313
After procedure	0.630 ± 0.615	1.000 (0.000 - 2.000) <sup>b</sup>	0.610 ± 0.567	1.000 (0.000 - 2.000) <sup>b</sup>	U=414.5	0.923
1th-hour VAS	0.530 ± 0.629	0.000 (0.000 - 2.000) <sup>b</sup>	0.570 ± 0.634	0.500 (0.000 - 2.000) <sup>b</sup>	U=406	0.806
2nd hour VAS	0.130 ± 0.346	0.000 (0.000 - 1.000) <sup>b</sup>	0.250 ± 0.518	0.000 (0.000 - 2.000) <sup>b</sup>	U=384	0.393
4th hour VAS	0.000 ± 0.000	0.000 (0.000 - 0.000) <sup>b</sup>	0.250 ± 0.518	0.000 (0.000 - 2.000) <sup>b</sup>	U=330	<b>0.008</b>
6th hour VAS	0.000 ± 0.000	0.000 (0.000 - 0.000) <sup>b</sup>	0.250 ± 0.585	0.000 (0.000 - 2.000) <sup>b</sup>	U=345	<b>0.016</b>
12th hour VAS	0.230 ± 0.504	0.000 (0.000 - 2.000) <sup>b</sup>	0.360 ± 0.559	0.000 (0.000 - 2.000) <sup>b</sup>	U=370.5	0.312
24th hour VAS	0.100 ± 0.305	0.000 (0.000 - 1.000) <sup>b</sup>	0.140 ± 0.356	0.000 (0.000 - 1.000) <sup>b</sup>	U=402	0.620
	$\chi^2=136.075$ <b>&lt;0.001</b>		$\chi^2=102.379$ <b>&lt;0.001</b>			

U: Mann-Whitney U test statistics,  $\chi^2$ : Friedman test statistics, a-b: No difference between times with the same letter within groups.

The sphenopalatine ganglion in the pterygopalatine fossa contains sympathetic, parasympathetic, and sensory fibres [12]. It can be accessed via the transnasal and transcutaneous approaches, but using only a long cotton applicator, it has been used to treat postspinal headaches [4,12,13]. This ganglion block is thought to produce vasoconstriction by parasympathetic block and prevent postspinal headache [14]. Although various concentrations of local anaesthetics have been tried, the largest case series was reported by Cohen et al. with 4% lidocaine and 5% lidocaine ointment applications [4,13]. The applicators were placed in the nose, and waited 10 minutes. This sphenopalatine ganglion block did not require an epidural blood patch in 89% of patients. In our study, we used a 10% lidocaine ampoule, dipped our applicator in a 10% lidocaine ampoule and had the patient wait at least 10 minutes. In our study, an epidural blood patch was not required in any cases with sphenopalatine ganglion block. There was no need for a secondary or tertiary blood patch. In a study by Puthenveetil et al. [15], they divided 20 obstetric patients with postspinal headaches into 2 groups. One group received drug treatment with analgesics and methylxanthines; the other received sphenopalatine ganglion block. They found that VAS scores significantly regressed within 5 minutes of the procedure in the block group. They found that pain scores were low in all cases with sphenopalatine ganglion block during all periods when pain scores were measured. The authors reported that sphenopalatine ganglion block is a highly effective alternative to medical therapy in treating postspinal headaches. In our study, pain scores at the 30th minute, 1st hour, 2nd hour, 12th hour, and 24th hour (except for the 4th and 6th hours) after the procedure were as effective as the epidural blood patch. When comparing the VAS scores in all periods in which intraoperative measurements were taken, it was found that the difference between the value before the procedure and all values after the procedure was significant. Our results are in perfect harmony with the findings in the literature.

When we look at the literature, we find case series in which sphenopalatine ganglion block treats postspinal headaches and persistent ones caused by intracranial hypotension. Case series report that block of the sphenopalatine gan-

glion effectively terminates headache [16-18].

A literature review shows the epidural blood patch treats both postspinal headache and intracranial hypotension [19-21].

## Conclusion

The epidural blood patch is the gold standard in treating postspinal headaches. Nonetheless, it is a difficult procedure since it is an invasive procedure. Sphenopalatine ganglion block is a treatment method resembling the epidural blood patch in treating postspinal headaches. It can be used as an alternative treatment method in cases that do not accept treatment with the epidural blood patch. As postspinal headache mostly occurs in obstetrics patients, it can be safely used to protect a newborn mother and the baby from the side effects of drugs that pass into the breast milk.

## Ethical approval

Ethical approval was obtained from the Ordu University Clinical Research ethics committee for our study (Date: 18/03/2021 Decision No: 2021/71).

## References

1. Kent S, Mehaffey G. Transnasal sphenopalatine ganglion block for the treatment of postdural puncture headache in the ED. *Am J EmergMed* 2015;33:1714.e1–1714.e2.
2. Olsen J, Boussier MG, Diener HC. The International Classification of Headache Disorders: 2 nd edition. *Cephalalgia* 2004; 24:9–160.
3. Bezov D, Lipton RB, Ashina S. Post-dural puncture headache: part I diagnosis, epidemiology, etiology, and pathophysiology. *Headache*. 2010; 50; 1144-1152.
4. Cohen S, Ramos D, Grubb W, Mellender S, Mohiuddin A, Chiricolo A. Sphenopalatine Ganglion Block. *Reg Anesth Pain Med*. 2014; 39(6): 563.
5. Gonçalves LM, Godinho PM, Durán FJ, Valente EC. Sphenopalatineganglionblockbytransnasalapproach in postdural puncturehead-ache. *J ClinAnesth* 2018;48:50.
6. Mehta D, Leary MC, Yacoub HA, El-Hunjul M, Kincaid H, Koss V, et al. TheEffect of RegionalAnestheticSphenopalatineGanglionBlock on Self-ReportedPain in PatientsWithStatusMigrainosus. *Headache* 2019;59:69–76.
7. Camann WR, Murray RS, Mushlin PS, Lambert DH. Effects of oral caffeine on postdural puncture headache. A doubleblind, placebo-controlled trial. *Anesth Analg* 1990;70(2):181- 4.

8. Abouleish E, Vega S, Blendinger I, Tio TO. Long-term followup of epidural blood patch. *Anesth Analg* 1975;54(4):459-63.
9. Pirbudak, L., Uğur, M. G., Kaya Uğur, B., Kul, S., & Ganidağlı, S. Evaluation of affecting factors and the effectiveness of treatment in cases with post-dural puncture headache who underwent epidural blood patch. *Agri*, 2014;26(3), 101-6.
10. Karaaslan K, Yılmaz F, Gülcü N, Koçoğlu H. FESS olgularında bilateral sfenopalatin ganglion blokajının postoperatif ağrı, bulantı-kusma, boğaz ağrısı ve laringospazm üzerine etkileri. *Anestezi Dergisi*.2008;16(2):95-98.
11. Levin D, Acquadro M, Cerasuolo J, Gerges FJ. Persistent Coronavirus Disease 2019 Headache Relieved with Sphenopalatine Ganglion Block. *Turk J Anaesthesiol Reanim*. 2022;50(Supp1):68-70. doi:10.5152/TJAR.2022.21318.
12. Kent S, Mehaffey G. Transnasal sphenopalatine ganglion block for the treatment of postdural puncture headache in obstetric patients. *J Clin Anesth*. 2016; 34: 194-6.
13. Peterson JN, Schames J, Schames M, King E. Sphenopalatine ganglion block: a safe and easy method for the management of orofacial pain. *Cranio*. 1995; 13(3): 177-81.
14. Edvinsson L. Innervation and effects of dilatory neuropeptides on cerebral vessels. *New aspects. Blood Vessels*.1991; 28(1-3): 35-45.
15. Puthenveetil N, Rajan S, Mohan A, Paul J, Kumar L. Sphenopalatine ganglion block for treatment of post-dural puncture headache in obstetric patients: An observational study. *Indian J Anaesth* 2018;62:972-7.
16. Bhargava T, Kumar A, Rastogi A, Srivastava D, Singh TK. A Simple Modification of Sphenopalatine Ganglion Block for Treatment of Postdural Puncture Headache: A Case Series. *Anesth Essays Res*. 2021;15(1):143-145. doi: 10.4103/aer.aer\_67\_21. Epub 2021 Aug 30. PMID: 34667362; PMCID: PMC8462416.
17. Rocha-Romero A, Roychoudhury P, Cordero RB, Mendoza ML. Bloqueio do gânglio esfenopalatino autoaplicado para cefaleia pós-punção dural: relato de quatro casos [Self-applied sphenopalatine ganglion block for postdural puncture headache: four case reports]. *Braz J Anesthesiol*. 2020 Sep-Oct;70(5):561-564. doi: 10.1016/j.bjan.2020.07.002. Epub 2020 Sep 16. PMID: 33032805; PMCID: PMC9373270.
18. Amighi D, Majedi H, Tafakhori A, Orandi A. The Efficacy of Sphenopalatine Ganglion Block and Radiofrequency Denervation in the Treatment of Cluster Headache: A Case Series. *Anesth Pain Med*. 2020 Nov 22;10(6):e104466. doi: 10.5812/aapm.104466. PMID: 34150572; PMCID: PMC8207843.
19. Leung LWL, Chan YCD, Chan TMD. Lumbar epidural blood patch: An effective treatment for intracranial hypotension. *Surg Neurol Int*. 2022 Nov 11;13:517. doi: 10.25259/SNI\_795\_2022. PMID: 36447895; PMCID: PMC9699889.
20. Choi SH, Lee YY, Kim WJ. Epidural blood patch for spontaneous intracranial hypotension with subdural hematoma: A case report and review of literature. *World J Clin Cases*. 2022 Jan 7;10(1):388-396. doi: 10.12998/wjcc.v10.i1.388. PMID: 35071543; PMCID: PMC8727273.
21. Masourou Z, Papagiannakis N, Mantzikopoulos G, Mitsikostas DD, Theodoraki K. Treating Spontaneous Intracranial Hypotension with an Anesthetic Modality: The Role of the Epidural Blood Patch. *Life (Basel)*. 2022 Jul 23;12(8):1109. doi: 10.3390/life12081109. PMID: 35892911; PMCID: PMC9331680.