Ann Med Res

Current issue list available at Ann Med Res

Annals of Medical Research

journal page: annalsmedres.org

Examination of thoracic deformities in patients with different clinical types of cerebral palsy

Selma Solgun Dag [a], Davut Ozbag [b], Egemen Kizilay [c], Sevda Canbay Durmaz [d,*]

[a]Siirt University, Faculty of Medicine, Department of Anatomy, Siirt, Türkiye
[b]Adıyaman University, Faculty of Medicine, Department of Anatomy, Adıyaman, Türkiye
[c]Malatya Training and Research Hospital, Department of Physical Therapy and Rehabilitation, Malatya, Türkiye
[d]Mardin Artuklu University, Faculty of Medicine, Department of Anatomy, Mardin, Türkiye
*Corresponding author: sevdacnby@hotmail.com (Sevda Canbay Durmaz)

MAIN POINTS

- Thoracic deformities in cerebral palsy are very important because they are life-threatening.
- In thoracic deformities, PE deformity was the most common in the anterior chest wall, while scoliosis was seen in spinal deformities.
- In CP, chest deformity evaluation should be done at an early age. Measurements should be evaluated by comparing over the years.

Cite this article as: Solgun Dag S, Ozbag D, Kizilay E, Canbay Durmaz S. Examination of thoracic deformities in patients with different clinical types of cerebral palsy. *Ann Med Res*. 2025;32(12):521--527. doi: 10.5455/annalsmedres.2025.06.148.

ABSTRACT

Aim: Cerebral Palsy is a clinical condition that causes permanent but non-progressive damage to the developing brain and can affect multiple systems. This study aimed to evaluate functional levels by assessing thoracic deformities across different clinical types of cerebral palsy (CP) and by gender, while also comparing anthropometric measurements between individuals with CP and a healthy control group.

Materials and Methods: Between the ages of 6 and 12 years, a total of 154 patients diagnosed with cerebral palsy (91 males, 63 females) and 40 healthy individuals (20 males, 20 females) were included in the study. Demographic characteristics, clinical type of CP, secondary findings, thoracic deformity, anthropometric measurements, and functionality levels were obtained from the patients. A tape measure and caliper were used for anthropometric measurements.

Results: The results indicated that the spastic type was the most prevalent clinical presentation of CP, with intellectual disability being the most common secondary problem. Among thoracic deformities, pectus excavatum was the most frequent anterior chest wall deformity, observed in 9.52% of females and 16.48% of males. Scoliosis was the most common spinal deformity, affecting 26.98% of females and 21.98% of males. Functionally, most patients were classified at GMFCS level II and Ambulation Group 1, although thoracic deformities were more prevalent in Group 2 patients. Furthermore, anthropometric measurements of patients with CP were significantly lower than those of healthy individuals, with statistically significant differences observed between Group 1, Group 2, and the healthy control group ($p<0.05$).

Conclusion: Cerebral palsy has a substantial impact on anthropometric measurements, musculoskeletal integrity, and the functional performance of the patients. Consequently, regular monitoring of the thoracic area is essential. The inclusion of thoracic evaluations in routine follow-up and treatment plans will likely have a positive impact on the disease's progression.

Keywords: Anthropometry, Functionality, Cerebral palsy, Thoracic deformity

Received: Jun 16, 2025 **Accepted:** Aug 28, 2025 **Available Online:** Dec 25, 2025

Copyright © 2026 The author(s) - Available online at annalsmedres.org. This is an Open Access article distributed under the terms of Creative Commons Attribution-NonCommercial-NoDerivatives 4.0 International License.

INTRODUCTION

Cerebral Palsy (CP) is a group of permanent disorders associated with non-progressive issues in the developing fetal or infant brain, leading to activity limitations that persist throughout life in movement and posture development [1]. Children with CP are generally classified into pyramidal (spastic) and extrapyramidal (non-spastic) types, based on the location and nature of neurological damage. Spastic CP results from corticospinal tract injury and is characterized by increased muscle tone and stiffness, while extrapyramidal CP involves damage to the basal ganglia or cerebellum, causing movement disorders. The non-spastic subgroup includes dyskinetic, ataxic, and hypotonic types. This classification supports individualized assessment and guides functional and therapeutic planning. Spasticity is very common in CP, accounting for 70-80% of cases [2].

The etiology is unknown in 30-40% of CP cases. It has been observed that the most significant cause of CP is prenatal

pathologies in 70-80% of cases. Among these, prematurity is the most common [3]. Motor disorders are often accompanied by secondary problems in CP. A heterogeneous picture emerges, as it may include neurological, psychological, behavioral, social, nutritional, and other issues [4].

The healthy growth and development of the spine happen alongside well-coordinated systems. If the spine experiences uneven muscle strength during growth, deformity can occur [5]. In neuromuscular diseases, abnormal loads result from muscle imbalance in the spine. This imbalance causes asymmetric growth of the vertebral bodies in individuals with immature skeletal systems. Spinal deformity occurs more frequently in CP patients than in the general population. The rate varies depending on the severity of the neurological condition. The incidence of spinal deformity in all CP patients is 25% [6].

Anterior chest wall deformities result from the abnormal development or deformation of the thoracic skeleton. In most cases, these deformities do not cause significant or life-threatening functional impairment of intrathoracic organs [7].

The primary objective of this study is to evaluate thoracic deformities and functional levels in children diagnosed with various clinical types of cerebral palsy—a condition known to affect multiple physiological systems—while examining variations based on gender. A secondary objective is to compare anthropometric measurements between the cerebral palsy group and a healthy control cohort to identify significant disparities.

(a) Round Back: Characterized by an exaggerated thoracic kyphosis, leading to a posterior convex curvature of the upper spine and slouched posture.

(b) Pectus Carinatum: Also known as "keel chest," this deformity involves anterior protrusion of the sternum and costal cartilages, resulting in a rigid and elevated chest wall appearance.

Figure 1. Visual representation of two distinct thoracic deformities commonly encountered in children with spastic CP.

MATERIALS AND METHODS

Study design and ethical approval

This study was conducted in accordance with the principles of the Declaration of Helsinki. Ethical approval was obtained from the Inonu University Health Sciences Non-Interventional Clinical Research Ethics Committee (decision no. 2021/1001). The study is based on a doctoral thesis completed at Inönü University. After providing comprehensive information about the study's objectives and procedures, written informed consent was obtained from the parents or legal guardians of all participants.

Participants and recruitment

This study included 154 children (91 male, 63 female) aged 6-12 years with a diagnosis of cerebral palsy (CP) and 40 age-matched healthy controls (20 male, 20 female). Participants with CP were recruited from five different rehabilitation centers in Malatya using a purposive sampling method. This non-probability technique allowed for the targeted enrollment of individuals who met the specific inclusion criteria for the study.

Individuals were excluded from the study if they had received botulinum toxin injections within the last six months, had a co-existing lung disease, a history of thoracic surgery, or short-extremity stature.

Data collection and assessments

For each patient with CP, the following data were collected: demographic information, clinical type of CP, secondary medical findings, and Gross Motor Function Classification System (GMFCS) level.

- Thoracic Deformity Assessment: The presence of tho-

https://doi.org/10.5455/annalsmedres.2025.06.148

racic deformities (Figure 1a, 1b) was determined by a physical therapy doctor through a comprehensive clinical protocol that combined visual inspection with radiological imaging to ensure diagnostic accuracy.

- Gross Motor Function Classification System (GMFCS): The GMFCS scale for the 6-12 age range was used to classify the functional mobility of the patients. The scale consists of five levels, with Level I representing the highest level of function and Level V representing the most limited. For analytical purposes, patients were divided into two groups based on their ambulation capacity: Group 1 (GMFCS levels I-III), consisting of patients who can walk, and Group 2 (GMFCS levels IV-V), consisting of patients who cannot walk [8].
- Anthropometric Measurements: To enhance reliability and minimize observational bias, all anthropometric measurements were conducted by two independent observers using a standard 1.5-meter tape measure and a Harpenden caliper.

Anthropometric measurement procedures

- Chest Circumference: Measured with a tape measure passing horizontally at the level of the xiphoid process and below the axilla during normal, quiet breathing [9].
- Abdominal Circumference: Measured at the level of the umbilicus with the participant in a supine position.
- Shoulder Circumference: Measured around the shoulder at the most prominent point of the deltoid muscle, passing under the acromion [10].
- Thorax Width: Measured from the anterior aspect at the level of the angulus costae of the 6th rib using a digital caliper.
- Shoulder Width: Measured from the posterior aspect, with the caliper ends placed on the most prominent parts of the deltoid muscles while the arms were relaxed at the sides [11].
- Biacromial Width: Measured from the posterior aspect, with the caliper ends placed on the most lateral points of the acromion processes [10].

Statistical analysis

All statistical analyses were performed using IBM SPSS Statistics (version 26.0).

Quantitative data were summarized as mean ± standard deviation for normally distributed variables and as median (minimum–maximum) for non-normally distributed data. Qualitative variables were expressed as frequencies and percentages. The Shapiro-Wilk and Kolmogorov-Smirnov tests were used to assess the normality of data distribution. For comparing two groups, the Independent Samples t-test was used for normally distributed variables, while the Mann-Whitney U test was used for non-parametric data. For categorical variables, the Pearson Chi-square test was used; if expected cell counts were low, Fisher's exact test was applied.

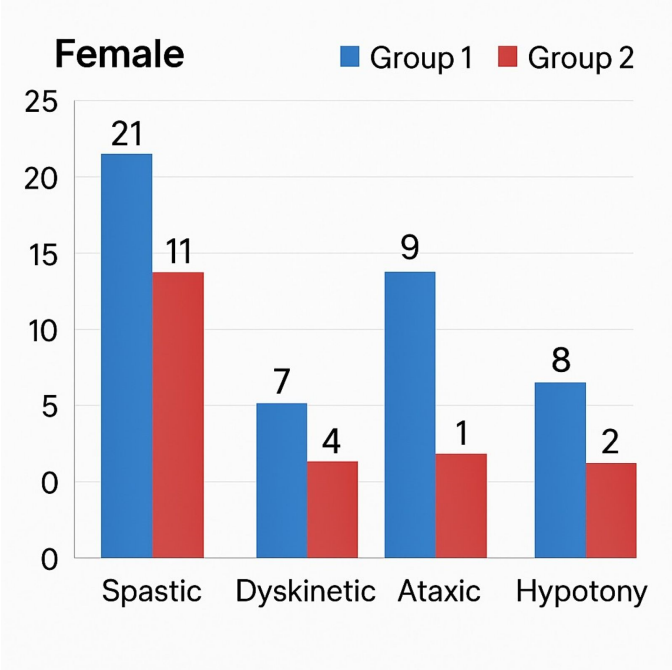

(a) Female.

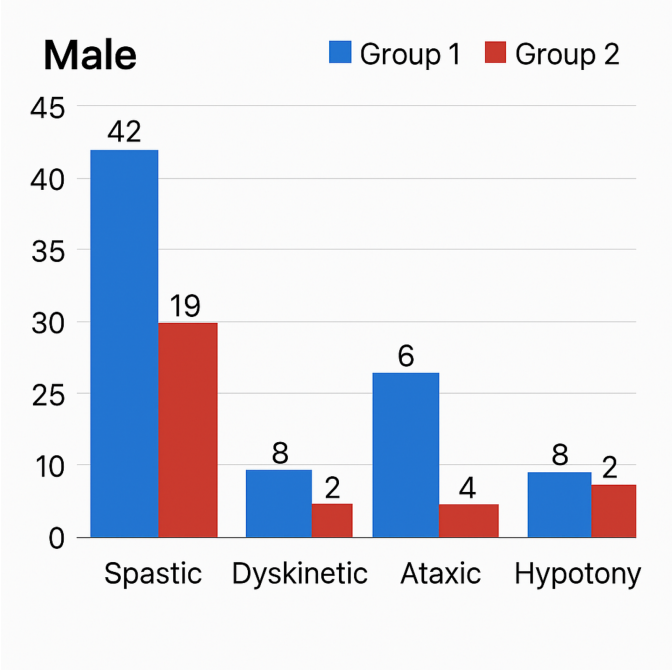

(b) Male.

Figure 2. GMFCS Group 1 and Group 2 distributions of the patient group by gender. (Group 1 includes children with higher functional mobility (Levels I and II), while Group 2 represents those with greater motor limitations (Levels III to V). Notable differences in subgroup prevalence may reflect gender-based variation in clinical presentation and severity).

https://doi.org/10.5455/annalsmedres.2025.06.148

Table 1. Distribution of thoracic deformities in the patient group by gender.

Thoracic Deformity	Female n(%)				Male n(%)				p-value
	Spastic	Dyskinetic	Ataxic	Hypotonic	Spastic	Dyskinetic	Ataxic	Hypotonic	
Kyphosis	1 (3.13)	0 (0.00)	0 (0.00)	0 (0.00)	5 (8.20)	2 (20.00)	0 (0.00)	0 (0.00)	0.048
Scoliosis	10 (31.25)	3 (27.27)	2 (20.00)	2 (20.00)	12 (19.67)	2 (20.00)	2 (20.00)	4 (40.00)	0.037
Hyperlordosis	3 (9.38)	0 (0.00)	0 (0.00)	0 (0.00)	6 (9.84)	0 (0.00)	0 (0.00)	0 (0.00)	0.092
Round Back	2 (6.25)	0 (0.00)	0 (0.00)	1 (10.00)	4 (6.56)	0 (0.00)	2 (20.00)	2 (20.00)	0.066
Flat Back	2 (6.25)	0 (0.00)	0 (0.00)	1 (10.00)	3 (4.92)	2 (20.00)	0 (0.00)	1 (10.00)	0.085
Pectus Excavatum	3 (9.38)	1 (9.09)	0 (0.00)	2 (20.00)	11 (18.03)	0 (0.00)	1 (10.00)	3 (30.00)	**0.022***
Pectus Carinatum	2 (6.25)	0 (0.00)	0 (0.00)	1 (10.00)	6 (9.84)	1 (10.00)	2 (20.00)	1 (10.00)	0.059

*Calculated using Pearson Chi-square or Fisher's exact test depending on expected cell counts. Values in bold indicate statistically significant group differences (p = 0.022).

Table 2. Distribution of Gross Motor Function Classification System (GMFCS) levels by gender in the patient group.

GMFCS	Female n(%)				Male n(%)				p-value
	Spastic	Dyskinetic	Ataxic	Hypotonic	Spastic	Dyskinetic	Ataxic	Hypotonic	
Level I	4 (12.50)	0 (0.00)	0 (0.00)	3 (30.00)	18 (29.51)	0 (0.00)	0 (0.00)	0 (0.00)	**0.021***
Level II	11 (34.38)	2 (18.18)	3 (30.00)	3 (30.00)	18 (29.51)	3 (30.00)	2 (20.00)	1 (10.00)	0.133
Level III	6 (18.75)	5 (45.45)	6 (60.00)	2 (20.00)	6 (9.84)	5 (50.00)	4 (40.00)	1 (10.00)	**0.038***
Level IV	3 (9.38)	2 (18.18)	1 (10.00)	0 (0.00)	4 (6.56)	1 (10.00)	3 (30.00)	1 (10.00)	0.092
Level V	8 (25.00)	2 (18.18)	0 (0.00)	2 (20.00)	15 (24.59)	1 (10.00)	1 (10.00)	7 (70.00)	**0.011***

* Derived using Pearson Chi-square or Fisher's exact test depending on cell frequencies. Bold values indicate statistically significant differences (p<0.05) across gender and clinical types.

Table 3. Thoracic deformity distribution of patients in Group 1 and Group 2 by gender.

Thoracic Deformity	Female n(%)		Male n(%)		p-value
	Group 1	Group 2	Group 1	Group 2	
Kyphosis	0 (0.00)	1 (5.56)	4 (6.90)	3 (9.09)	0.291
Scoliosis	9 (20.00)	8 (44.44)	5 (8.62)	15 (45.45)	**0.014***
Hyperlordosis	2 (4.44)	1 (5.56)	6 (10.34)	0 (0.00)	**0.036***
Round Back	2 (4.44)	1 (5.56)	0 (0.00)	8 (24.24)	**0.019***
Flat Back	2 (4.44)	1 (5.56)	4 (6.90)	2 (6.06)	0.837
Pectus Excavatum	1 (2.22)	5 (27.78)	6 (10.34)	9 (27.27)	**0.022***
Pectus Carinatum	1 (2.22)	2 (11.11)	3 (5.17)	7 (21.21)	**0.038***

*Indicates the statistical significance of deformity distribution between Group 1 and Group 2 (by gender), calculated using Pearson Chi-square or Fisher's exact tests. Bold values denote statistical significance (p<0.05).

Table 4. Anthropometric measurements and significance values of female Group 1 and Group 2 patients and the healthy group.

Anthropometric Measurements	Axillar Circumference	Xiphoid Circumference	Subcostal Circumference	Abdominal Circumference	Shoulder Circumference	Thorax Width	Shoulder Width	Biacromial Circumference
Group 1	63[ab*] (52-95)**	63[ab] (54-86)	57[ab] (45-86)	57[ab] (42-95)	24[b] (15-33)	16[ab] (11-24)	25[ab] (18-37)	19[ab] (14-30)
Group 2	58.50[b] (48-71)	58[b] (48-72)	52[b] (43-63)	49.50[b] (42-63)	21[b] (7-28)	14[b] (11-19)	22[b] (18-28)	17[b] (12-24)
Healthy	69.50 (58-96)	67.50 (58-89)	62.50 (52-86)	66 (53-90)	26.50 (21-42)	18 (14-27)	27.50 (22-40)	23 (18-29)
p***	**<0.001**	**<0.001**	**<0.001**	**<0.001**	**0.00334**	**<0.001**	**<0.001**	**<0.001**

*[a]: Different according to the dyskinetic group, [b]: Different according to the ataxic group, [c]: Different according to the hypotony group, [d]: Different according to the healthy group. **: Variables, 'median (min.-max.)' ***:Kruskal Wallis test.

The Kruskal-Wallis test was used for comparisons across more than two independent groups. A p-value of less than 0.05 was considered statistically significant. An a priori power analysis indicated that a minimum of 64 participants per group was required to achieve 80% power with a medium effect size (Cohen's d = 0.5) at a significance level of $\alpha = 0.05$. The sample size was increased to ensure adequate statistical power for subgroup analyses. Prior to analysis, all data were pre-processed to identify and handle outliers, missing values, and inconsistencies

https://doi.org/10.5455/annalsmedres.2025.06.148

Table 5. Anthropometric measurements and significance values of male Group 1 and Group 2 patients and the healthy group.

Anthropometric Measurements	Axillar Circumference	Xiphoid Circumference	Subcostal Circumference	Abdominal Circumference	Shoulder Circumference	Thorax Width	Shoulder Width	Biacromial Circumference
Group 1	64.50[b*] (53-91)**	63.50[b] (53-88)	57[b] (42-85)	56.50[ab] (46-90)	23[b] (16-35)	16[b] (11-24)	24[b] (19-35)	18.50[b] (13-27)
Group 2	61[b] (49-78)	62[b] (47-78)	56[b] (42-75)	52[b] (39-73)	21[b] (12-34)	15[b] (10-25)	24[b] (17-35)	18[b] (14-31)
Healthy	72.50 (59-90)	69.50 (61-89)	65.50 (53-84)	66.50 (51-87)	25.50 (21-33)	18.50 (16-28)	29 (24-36)	23 (18-27)
p***	**<0.001**	**<0.001**	**<0.001**	**<0.001**	**0.00379**	**<0.001**	**<0.001**	**<0.001**

*[a]: Different according to the dyskinetic group, [b]: Different according to the ataxic group, [c]: Different according to the hypotony group, [d]: Different according to the healthy group. **: Variables, 'median (min.-max.)' ***:Kruskal Wallis test.

RESULTS

A total of 154 CP patients (41% female, 59% male) and 40 healthy individuals (50% female, 50% male) were included in the present study. The CP patients comprised the "patient group," while healthy individuals formed the "control group." According to GMFCS classifications, Levels I–III (Group 1) included ambulatory patients, and Levels IV–V (Group 2) comprised non-ambulatory individuals.

Height and weight were significantly lower in the patient group compared to the control group. Although BMI values were also lower in the patient group, the difference did not reach statistical significance.

Distribution of CP clinical subtypes among females included spastic (n = 32), dyskinetic (n = 11), ataxic (n = 10), and hypotonic (n = 10) presentations. Among males, subtypes were spastic (n = 61), dyskinetic (n = 10), ataxic (n = 10), and hypotonic (n = 10). Secondary conditions frequently observed in CP patients included intellectual disability, speech impairment, behavioral problems, swallowing and drooling difficulties, epilepsy, and visual impairments.

Thoracic deformity distribution by gender is shown in Table 1, while GMFCS levels are provided in Table 2. The distribution of Group 1 and Group 2 patients by gender is visualized in Figure 2, and Table 3 details thoracic deformity distributions across these functional groups. Anthropometric measurements and their statistical comparisons by gender are presented in Tables 4 and 5.

DISCUSSION

This study provided a comprehensive evaluation of thoracic deformities, functional capacity, and anthropometric characteristics in children with various clinical subtypes of cerebral palsy (CP), with a specific focus on gender differences. Unlike previous research that has concentrated primarily on extremity deformities, our study emphasized structural deviations in the spinal and anterior chest wall—areas often overlooked in routine clinical evaluations. Our findings confirm that children with CP exhibit significantly altered anthropometric profiles and a high prevalence of thoracic deformities, the severity of which correlates with functional impairment.

In our cohort, height and weight were significantly lower in individuals with CP compared to healthy controls, a finding consistent with the work of Uygur et al. [12]. However, while we observed lower (BMI) values in the patient group, the difference did not achieve statistical significance. The prevalence of secondary conditions in our sample—such as intellectual disability, speech difficulties, and epilepsy—aligns with trends reported by Durmaz et al., reinforcing the multi-systemic nature of CP. These comorbidities likely compound musculoskeletal dysfunction, limiting growth and contributing to the development of thoracic deformities [13-15].

The rate of thoracic and spinal deformities in our study was notable. We identified pectus excavatum (PE) in 9.52% of females and 16.48% of males, and scoliosis was the most common spinal deformity. This contrasts with earlier studies, such as by Ersöz et al. [16], who found no anterior chest wall deformities, and Öneş et al. [17], who reported a lower overall rate of spinal deformities. We attribute the development of these deformities to a combination of factors inherent to CP, including biomechanical imbalances, asymmetrical muscle tone, impaired proprioception, and postural instability against gravity.

Functionally, our patient cohort demonstrated a higher level of motor ability compared to those in previous Turkish studies. While Karabay et al. [9] and Atay et al. [18] reported a majority of patients in GMFCS Levels III–V, our study found that most participants (71.43% of females and 63.74% of males) were classified in Group 1 (GMFCS Levels I–II). This encouraging trend may reflect advancements in early diagnosis and rehabilitation services. As expected and consistent with the literature [8], our results confirmed a strong relationship between functional level and deformity prevalence; both anterior chest wall and spinal deformities were significantly more common in non-ambulatory Group 2 patients (GMFCS IV-V). As patients' motor independence decreased, the rates of deformity increased.

Our anthropometric findings largely support previous research showing reduced growth parameters in children with CP [10,14]. We observed significantly lower chest (axillary, xiphoid, subcostal), abdominal, and shoulder circumferences,

https://doi.org/10.5455/annalsmedres.2025.06.148

as well as reduced thorax, shoulder, and biacromial widths. These results expand on the findings of Uygur et al. [12], as we also identified significant reductions in xiphoid and subcostal circumferences, which they did not. This discrepancy may be due to our inclusion of more severely affected spastic and dyskinetic subtypes. Furthermore, contrary to the findings of Kosif et al. [19], who reported no significant differences in girls, our study found lower anthropometric values in both males and females. An exception was observed in females with ataxic CP, whose measurements were closer to controls. This can likely be explained by their high functional status, as 90% of them were in GMFCS Level I. This highlights the critical role that motor function plays in musculoskeletal development.

Limitations

This study has certain limitations that should be acknowledged. The sample size, while substantial, may limit the generalizability of our findings to the broader CP population. Additionally, some observed thoracic deformities were complex and could not be classified into standard categories, which may have influenced our reported prevalence rates. Future longitudinal studies are warranted to track the progression of these deformities over time and to assess their impact on respiratory function and quality of life.

CONCLUSION

Cerebral palsy significantly impacts musculoskeletal integrity, anthropometric development, and functional capacity. Our findings underscore the high prevalence of thoracic deformities in this population and their strong correlation with motor impairment. Therefore, routine thoracic evaluation should be integrated into standard physiotherapy assessments for children with CP. Regular monitoring can aid in the early detection of deformities, allowing for timely interventions that may positively influence the disease trajectory and improve long-term outcomes.

This study was previously presented as a oral presentation at 4rd International 33rd National Turkish Biophysics Congress (31 August-1-3 September Adıyaman).

Ethics Committee Approval: The study was conducted afterobtaining the necessary permissions Inonu University Health Sciences Non-Interventional Clinical Research Ethics Committee with the decision number 2021/1001.

Informed Consent: After a detailed explanation of the study, written informed consent was obtained from the participants and their families. Additionally, written informed consent for imaging was obtained from the patient's legal guardian.

Peer-review: Externally peer-reviewed.

Conflict of Interest: There is no conflict of interest between the authors.

Author Contributions: Conception: S.S.D, E.K, S.C.D; Design: S.S.D; E.K; Supervision: S.S.D, D.Ö, E.K, S.C.D; Fundings: S.S.D; Materials: S.S.D,S.C.D; Data Collection and/or Processing: S.S.D, E.K; Analysisand/or Interpretation: D.Ö,S.C.D; Literature Review: S.C.D; Writing: S.S.D; Critical Review: D.Ö, E.K,S.C.D.

Financial Disclosure: This study did not receive any financial support.

REFERENCES

1. Kim F, Maitre N; Cerebral Palsy Foundation. A Call for Early Detection of Cerebral Palsy. *Neoreviews.* 2024;25(1):e1-e11. doi: 10.1542/neo.25-1-e1.
2. Modlesky CM, Matias AB. Muscle in children with cerebral palsy: current evidence, knowledge gaps, and emerging research opportunities : Focus on Cerebral Palsy. *Pediatr Res.* 2024. doi: 10.1038/s41390-024-03422-x.
3. Dar H, Stewart K, McIntyre S, Paget S. Multiple motor disorders in cerebral palsy. *Dev Med Child Neurol.* 2024;66(3):317-325. doi: 10.1111/dmcn.15730.
4. Olmos-Gómez R, Calvo-Muñoz I, Gómez-Conesa A. Treatment with robot-assisted gait trainer Walkbot along with physiotherapy vs. isolated physiotherapy in children and adolescents with cerebral palsy. Experimental study. *BMC Neurol.* 2024;24(1):245. doi: 10.1186/s12883-024-03750-9.
5. Khalifeh K, Brown NJ, Pennington Z, Pham MH. Spinal Robotics in Adult Spinal Deformity Surgery: A Systematic Review. *Neurospine.* 2024;21(1):20-29. doi: 10.14245/ns.2347138.569.
6. Yoshida K, Kajiura I, Suzuki T, Kawabata H. Natural history of scoliosis in cerebral palsy and risk factors for progression of scoliosis. *J Orthop Sci.* 2018;23(4):649-652. doi: 10.1016/j.jos.2018.03.009.
7. Şirazi S, Heydar AM, Bezer M, Yüksel M. Correlation of anterior chest wall anomalies and spinal deformities: a comprehensive descriptive study. *Spine Deform.* 2024;12(6):1615-1622. doi: 10.1007/s43390-024-00918-8.
8. Sloane BM, Kenyon LK, Logan SW, Feldner HA. Caregiver perspectives on powered mobility devices and participation for children with cerebral palsy in Gross Motor Function Classification System level V. *Dev Med Child Neurol.* 2024;66(3):333-343. doi: 10.1111/dmcn.15718.
9. Atay Y. Serebral Paralizi'li Çocukların Farklı Klinik Tiplerinde Antropometrik Özelliklerin Değerlendirilmesi. Sağlık Bilimleri Enstitüsü, Protez Ortez Biyomekani Programı. Yüksek Lisans tezi, *Ankara: Hacettepe Üniversitesi.* 2006.
10. Otman AS, Demirel H, Sade A. Tedavi Hareketlerinde Temel Değerlendirme Prensipleri, 3. Baskı. Ankara. *Hacettepe Üniversitesi Fizik Tedavi ve Rehabilitasyon Yüksekokulu Yayınları.* 2003:11-53.
11. Díaz-Martínez AS, Vaquero-Cristóbal R, Albaladejo-Saura M, Esparza-Ros F. Effect of pre-season and in-season training on anthropometric variables, somatotype, body composition and body proportion in elite basketball players. *Sci Rep.* 2024;14(1):7537. doi: 10.1038/s41598-024-58222-4.
12. Uygur R, Özen OA, Baş O, Uygur E, Songur A. Hemiplejik serebral palsili çocuklarda gövde antropometrik ölçümlerinin değerlendirilmesi. *Int J Basic Clin Med.* 2015;1(1): 7-14.
13. Dormans J, Susman M, Özaras N, Yalçın S. Serebral Palsi Tedavi ve Rehabilitasyon, 1. Baskı. *Mas Matbaacılık.* İstanbul. 2000.
14. Durmaz SC, Karabulut AK, Güngör S, Fazlıoğulları Z, Uysal İİ, Doğan NÜ. Clinical evaluation of cerebral MRI findings in children with cerebralpalsy. *Ann Clin Anal Med.* 2022;13(10):1117-21. doi: 10.4328/acam.21228.
15. Taylor JB, Ingram DG, Kupfer O, Amin R. Neuromuscular Disorders in Pediatric Respiratory Disease. *Clin Chest Med.* 2024;45(3):729-747. doi: 10.1016/j.ccm.2024.02.021.

16. Ersöz M, Selçuk B, Gündüz R, Kurtaran A, Akyüz M. Decreased chest mobility in children with spastic cerebral palsy. *Turk J Pediatr*. 2006;48(4): 344-50. PMID: 17290570.
17. Öneş K, Çelik B, Çağlar N, Gültekin Ö, Yılmaz E, Çetinkaya B. Serebralpalsi polikliniğine müracaat eden hastaların demografik ve klinik özellikleri. *Türk Fiz Tip Rehab Derg*. 2008;54(1): 13-6.
18. Karabay İ, Şenlikci HB, Nazlıkul FGU, Tiftik TT, Ersöz M, Akkuş S. Serebralpalsili hastalarda fonksiyonel durum, serebralpalsi tipi ve antropometrik parametrelerin ilişkisi. *Turkish J Pediatr Dis*. 2020; 14(5): 417-21. doi: 10.12956/tchd.674754.
19. Kosif R, Eldeş N, Kutsal E, Aydemir C. On yaşındaki serebralpalsili çocuklarda farklı antropometrik ölçümlerle büyümenin değerlendirilmesi. *Yeni Tip Dergisi*. 2007; 24:35-8.

https://doi.org/10.5455/annalsmedres.2025.06.148